

History of Medicine

Razi's Description and Treatment of Facial Paralysis

Seyed Mahmood Tabatabaei MD¹, AbdolJalil Kalantar-Hormozi MD², Mohsen Asadi MD³

Abstract

In the modern medical era, facial paralysis is linked with the name of Charles Bell. This disease, which is usually unilateral and is a peripheral facial palsy, causes facial muscle weakness in the affected side. Bell gave a complete description of the disease; but historically other physicians had described it several hundred years prior although it had been ignored for different reasons, such as the difficulty of the original text language. The first and the most famous of these physicians who described this disease was Mohammad Ibn Zakaryya Razi (Rhazes). In this article, we discuss his opinion.

Keywords: facial paralysis, Rhazes, Iran

Introduction

The review of historical documents suggests that facial palsy is as old as human history and has been depicted in paintings, sculptures, masks, and papyri.¹ Although not a lethal disease, it could have an adverse effect on quality of life. Facial palsy causes facial asymmetry, distorting facial expression. An inability to close the eyelid could lead to conjunctivitis and blindness. However, up to the end of the 19th century, there was no surgical treatment available for this disease; thus many patients suffered from a lifelong affliction of facial palsy.² Even though surgical treatment for facial palsy was introduced in 19th century, modern microscopic surgical techniques during the past ten years have revolutionized its treatment.^{3,4}

Although in modern medical history this disease has been described by Charles Bell (1774 – 1842), a review of the old medical documents determined that it had been originally described by the Iranian physician, Ali Ibn Sahl Ibn Rabban Tabari (b: 807 – 808, d: 861 – 862).⁵

Razi (Rhazes) (865 – 925 AD) was the first physician in medical history, who gave a thorough description of facial palsy and suggested some treatments.

Afterwards, other Iranian scientists such as Avicenna (983 – 1035 AD) and Jorjani (12th century) also described this disease.^{6,7}

Mohammad Ibn Zakaryya Razi (Rhazes) was a respected

physician and scholar who authored the 26 volume series known as “Al-Hawi”. Razi was born in 865 AD in the ancient city of Rey (Ray) near Tehran, Iran. He was one of the most brilliant scientists, who authored more than 180 books in medicine and other scientific fields.

Razi has been credited with the discovery of alcohol and sulfuric acid, which have contributed to the progress of both medicine and chemistry.⁸

In his book, Al-Hawi, he described many different diseases (Figures 1) of which one of its topics was facial palsy (Figure 2). In order to show the accurateness of his description, below is a portion of the translated section of his book on facial palsy⁹⁻¹¹:

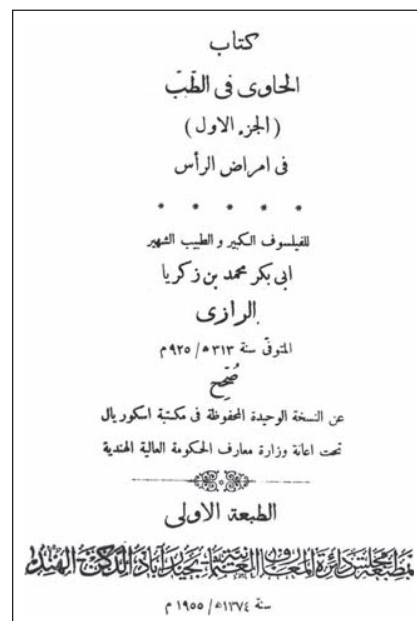


Figure 1. The front cover of Al-Hawi, Arabic version, published in 1955- India

Authors' affiliations: ¹Department of Psychiatry, Shahid Beheshti University of Medical Sciences, Tehran, Iran. ²Department of Plastic and Reconstructive Surgery, Head of Craniomaxillofacial Department, 15 Khordad Hospital, Shahid Beheshti University, Tehran, Iran. ³Department of Plastic and Reconstructive Surgery, 15 Khordad Hospital, Shahid Beheshti University, Tehran, Iran

•**Corresponding author and reprints:** Seyed Mahmood Tabatabaei MD, 15 Khordad Hospital, Shahid Beheshti University, Tehran, Iran. Tel: +98-218-890-9195, Fax: +98-218-890-9193, E-mail: smtabataba_md@yahoo.com

Accepted for publication: 11 November 2010

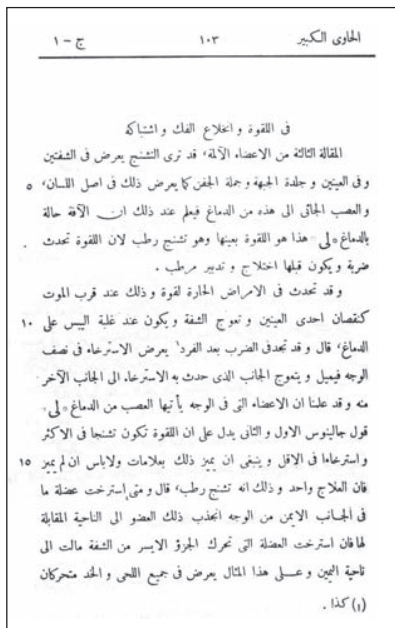

Figure 2. A chapter of Al-Hawi is devoted to facial palsy, Chapter 6, Volume1.

“Laghwa or facial palsy: this disease which occurs suddenly and half of the face has flaccid paralysis and distorts and deviates to the opposite side. Therefore if the muscle of left-side of lip is involved, lip is pulled to the right side, and that part of jaw and cheek are also affected.

This disease is called “spasmodic muscular cranious” or “spasmodic phrenicaus cranious” in Greek; and it means spasm in muscles of head.”

Symptoms and diagnostic clues

1. “The patient should be asked if the sensation of the affected side is the same as the other side or not? Also, it should be evaluated whether the sensation of the affected side is exaggerated or not.”
2. “If somebody feels pain in facial bones, cheek and skin it could be a preliminary symptom of mouth distortion. Therefore, cold exposure should be avoided and bloodletting should not be done.
3. It is possible that (muscular) twitches in the face be part of primary signs of this disease.
4. The frontal skin in the affected side could be taut so that previous wrinkles disappear or some new wrinkles appear. The patient is unable to close his eyelids and even if there is little motion the closure is not complete.
5. The face during smiling distorts and the eye is sunken and smaller in the affected side and there is constant tearing.
6. The patient chews with his unaffected side.
7. The patient’s speech is slurred and the patient has a low morale and looks defeated.

8. Some patients have headaches in temporal region (migraineous).
9. If we open the patient’s mouth and depress the tongue; the distal soft palate (uvula) is paralyzed and there are some excess secretions and discoloration.
10. There is a type of this disease which is bilateral.”

Prognosis

1. “Some patients recover without any treatment.
2. Some live with this disease without any other complication and it does not involve other nerves.
3. Some have clouding of consciousness and feel disability in their limbs.
4. Some experience paralysis of limbs in the affected side.
5. Some have cerebral stroke following this disease.
6. Some have died after being affected. But if a patient survives till the fourth day, he will not die of this disease.
7. If the left side is affected, it has a worse course.
8. If it is not recovered within six months, it will never be recovered. Some physicians state that its course is two months and some believe that if the left side disease lasts more than a month it won’t be cured.
9. Those who have complete involvement of the frontal part of their brain, could experience coma or subcoma.
10. If it is accompanied by lack of consciousness or slowing of body motions, it does not have a good prognosis. They don’t lose their hearing or visual sensations. Facial sensation does not alter.”

Some interesting cases

- “A man after a prolonged fasting and undergoing bloodletting was affected with a type of facial paralysis so that he could not close one eye. Although his mouth was not distorted he couldn’t hold water in his mouth. So, because the mouth was normal the disease was bilateral.
- Some people are more vulnerable to this disease. Bloodletting could lead to facial distortion, as the disease was seen in a fat old man and a eunuch after bloodletting.”

Razi also mentions: “I have seen some cases who have recovered without bed rest and despite their daily activities.”

Some treatments

1. “There are some medications that could be used for these patients.
2. The supportive measures are:
 - a) Patient should rest in a dark and warm place. In winter, patients should avoid cold and wind.
 - b) Application of warm and dry cloth on jaw and cer-

vical vertebra is useful and excessive use of this is advised.

c) The affected side should be wrapped and pulled to the other side. The skin of frontal area should be pulled down and with some warm oils should be massaged. Every hour the status of the lip should be assessed and kept in the correct position.

In the review of Iranian medical history, there is a brilliant scientist and scholar named Mohammad Ibn Zakaryya Razi (865 – 925 AD) who about 80 years prior to Avicenna had written many books on different medical subjects. Although before Razi, Tabari (260 AD) had also authored some medical books, it was Razi with his 26 volume “Al-Hawi” who opened new horizons in different aspects of medicine of which many of its contents are still applicable.¹²⁻¹⁷

In conclusion, this article has focused on one of the important subjects of facial paralysis, which had been described by Razi about one thousand years ago with such detail that it parallels our knowledge today.

His skillful description of the disease, its causes and symptoms in addition to a description of the rare bilateral involvement is admirable. Its case presentation, on the other hand, is also interesting. The recognition of the seventh cranial nerve, its route and differences between central and peripheral involvement are other astonishing features of his work. The point that if recovery does not occur within six months, therefore a permanent lesion would be present, is another important aspect of his study. Although medical treatment for the disease has not changed much, the only treatment option which has been added is the surgical approach to this disorder, which is still not infallible. This emphasizes the point of the insight and intelligence of scientists such as Razi who had described such diseases at that time despite obstacles and limitations for research and information transfer. Thus it is the duty and responsibility of contemporary scientists and physicians to meticulously review these works to avoid steps, which have been previously taken.^{18,19}

References

1. Resende LA, Weber S. Peripheral facial palsy in the past. *Arg Neuropsiquiatre*. 2008; **66**: 765 – 769.
2. van de Graaf RC, Nicolai JP. On the surgical treatment of facial paralysis in the early nineteenth century. *Plast Reconstr Surg*. 2008; **121**: 475 – 480.
3. Dieffenbach KM. Facial paralysis in the early Nineteenth Century. *Plast Reconstr Surg*. 2008; **122**: 995 – 996. author reply 996 – 997. *Plast Reconstr Surg*. 2008; **121**: 475 – 480.
4. Terzis JK, Olivares FS. Long-term outcomes of free-muscle transfer for smile restoration in adults. *Plast Reconstr Surg*. 2009; **123**: 877 – 888.
5. Thabari, Ali-bin-Sahl-bin-Rabban, al-Hekmah F. *Dar Al-Kotob-Al-Elmieh* [in Arabic]. Beirut, Lebanon; 2002: 143 – 144.
6. Ibn-Sina, Abdollah H. Facial paralysis chapter. *Al-Qanun Fi-Tebb Fasle-Fi-Al-Laghwa*. Tehran, Iran: Stone Printing; 1880.
7. Jorjani, Esmail S. *Al-Aghrasol-tebbiah*. 1st ed., Vol. 1. Tehran, Iran: Academy of Medical Science of I.R. of Iran; 2005: 495 – 498.
8. Modanlou Houchang D. A tribute to Zakaryya Razi (865 – 925 AD), an Iranian pioneer scholar. *Arch Iran Med*. 2008; **11**: 673 – 677.
9. Mohammad Ibn Zakaryya Razi. *Al-Hawi Al-Kabir Fi-Tebb*. 1st ed., Vol. 1, Dakan, India: Haydar-Abad Da-e-Ratol-ma-Aref Osmani Institute; 1955: 103 – 116.
10. Mohammad Ibn Zakaryya Razi. *Al-Hawi Al-Kabir Fi-Tebb* [in Persian]. 1st ed., Vol. 1. [Translated by Sayyed Mahmoud TabaTabaei] Tehran, Iran: Al-Hawi Pharmacy Institute; 1999: 117 – 128.
11. Mohammad Ibn Zakaryya Razi. *Abstract of Al-Hawi*. 1st ed., Vol. 1. Mashhad, Iran: Mashhad Medical University Press; 2008: 66 – 69.
12. Broumand B. The contribution of Iranian scientists to world civilization. Opinion. Available from: URL: file://F:\0026.htm
13. Azizi MH. The otorhinolaryngologic concepts as viewed by Rhazes and Avicenna, history of ancient medicine in Iran. Available from: URL: file://F:\0027.htm
14. Azizi MH, Nayernouri T, Azizi F. A brief history of the discovery of the circulation of blood in the human body. History of Medicine. Available from: URL: file://F:\0022.htm
15. Abbasi-Dezfouli A, Daneshvar-Kakhki A, Arab M, Javaherzadeh M, Shadmehr MB, Abbasi S, et al. Development of thoracic surgery in Iran. *Arch Iran Med*. 2007; **10**: 547 – 549.
16. Azizi F. Endocrinology and metabolism in the Islamic Republic of Iran. History of contemporary medicine in Iran. Available from: URL: file://F:\019.htm
17. Nayernouri T. Zakaryya Razi the Iranian physician and scholar. *Arch Iran Med*. 2008; **11**: 229 – 234.
18. Tabatabaei SM, Kalantar-Hormozi AJ. Headache in Al-Hawi of Razi, comparing to modern medical literature [in Persian]. *PaJouhesh Dar Pezeshki*. 2009; **33**: 1 – 4.
19. Tabatabaei SM, Kalantar-Hormozi AJ, Sedaghat MR. Ophthalmology in Al-Hawi of Razi, comparing to Modern Medical literature [in Persian]. *PaJouhesh Dar Pezeshki*. 2009; **33**: 59 – 63.