

# Breast Reconstruction with Contralateral Cutaneo-Glandular Flap

Kalantar Hormozi J<sup>1</sup>, Mozaffari N<sup>2</sup>, Mohammadsadeghi SH<sup>2</sup>, Fadaee Naeeni A<sup>3</sup>

## Abstract

The perfect method for breast reconstruction would be safe, reliable, reproducible, applicable to all patients, and would have no donor site morbidity. The ideal reconstructed breast would provide symmetric, permanent, and natural results.

There has been development and refinement of autogenous methods of breast reconstruction throughout the literature. The TRAM flap remains the most popular method of autogenous reconstruction. This popularity is due to the relative ease with which the procedure is performed but it has its own drawbacks. Other procedures include: Deep inferior epigastric artery perforator flap; free flaps (free TRAM flap; free superior gluteal myocutaneous flap); pedicled latissimus dorsi flap, etc.

We have reconstructed the breast in ten patients after mastectomy with a different technique which is cutaneoglandular flap from the contralateral normal breast. It has the advantage of using normal breast tissue for reconstruction in addition to reduction of a possible large breast the patient may have. It is almost without donor site morbidity and there is no need to reposition the patient intraoperatively. It is mostly used when the patient is reluctant to undergo a big operation. This technique can also be used when there are contraindications to other techniques.

In this paper, patients are presented who have undergone contralateral cutaneoglandular flap with an inferior pedicle and free nipple graft technique with fairly satisfactory results.

**Keywords:** breast reconstruction, breast cutaneoglandular flap, mastectomy, inferior pedicle

1. Professor of Maxillofacial Surgery, 15th Khordad Hospital, Shahid Beheshti University, (MC)  
2-Assistant professor , 15th Khordad Hospital, Shahid Beheshti Medical University, (MC)  
3. Plastic Surgeon, 15th Khordad Hospital, Shahid Beheshti University, (MC)

Corresponding author:  
Kalantar Hormozi,A.J

Email: Kalantari@yahoo.com

## Introduction

Mastectomy in women with breast cancer causes great psychological impact which includes feeling of body incompleteness, inconvenience in working and social communication, less sexual act and low spirit [1]. Conservative surgery or immediate breast reconstruction after modified radical mastectomy has been proposed in the attempt to avoid the negative impact of MRM on feminine body image [2]. The TRAM flap is the most common technique for autogenous breast reconstruction [3,4].

Its adipose tissue and skin quality closely mimic breast skin and fat.

Recent studies of the perforator flap have led to the development of the deep inferior epigastric artery perforator flap [5,6]. It uses the same skin island as the TRAM flap but preserves the rectus abdominis muscle and anterior rectus fascia, for less donor-site morbidity [7,8]. Other flaps from the same lower abdominal area, but based on the superficial inferior epigastric artery [9,10] or skin vessels above

the abdominal fascia (paraumbilical perforator flap),[11] have also been developed but have not gained popularity.

The first free-flap reconstruction of the breast was reported by Holmstrom [12]; however, Grotting et al [13] made it popular in 1989 with the use of free transverse rectus abdominis musculocutaneous (TRAM) flap.

Free tissue transfers surpassed pedicled reconstruction because of the improved blood supply, easier inset, and high free-flap success rates they offer [14,15].

The free superior gluteal myocutaneous flap is based on the gluteus maximus muscle.

We have reconstructed the breast in 10 patients after mastectomy with a totally different technique which is through cutaneoglandular flap from the contralateral normal breast.

In this paper, two patients are presented who have undergone breast reconstruction in this manner.

### The operation technique:

In order to determine the adequacy of pedicle length, the breast tip is approximated to the mastectomized site while the patient is in an upright position.

If the anticipated pedicle length is adequate, this method is used (figure 1).

An inferior cutaneo-glandular flap with the attached nipple-areola complex from normal breast is designed and then dissected in a way similar to mammoreduction with inferior pedicle technique.

The mastectomy scar is excised and the flap is transferred subcutaneously from the normal site, and is inset in the mastectomy site to make the new breast.

The donor site is closed primarily with side flaps.

After a period of approximately three weeks; the pedicle is cut and secondary revision of the flap is performed.

Nipple-areola complex with a diameter of 4 cm is harvested from the flap and used as a graft and fixed on the tip of the reduced normal breast. (Free nipple technique).

## Patients and Methods

### Cases:

**Case 1:** A 48-year-old woman with a history of modified radical mastectomy and axillary node dissection due to right breast tumor 5 years ago. The pathology of the tumor was ductal carcinoma and the patient passed courses of adjuvant therapy.

At the time of admission; the operated site had completely healed and no recurrence of tumor was present (figure 2).

The left breast was normal in examination and mammography had no significant findings.

The technique was applied and after making breast mound, conchal cartilage was used for nipple reconstruction (figure 2).

The patient has been followed for three years and the results have been satisfactory.

**Case 2:** A 50-year-old woman with a history of left modified radical mastectomy and axillary lymph node dissection due to ductal carcinoma 4 years ago.

Physical examination and mammography revealed no significant findings.

Her normal breast had good length and enough bulk for our technique.

Contralateral cutaneoglandular flap was used and the size of reconstructed breast was approximately equal to normal reduced breast.

Areola was reconstructed by a free nipple graft technique (figure 3).

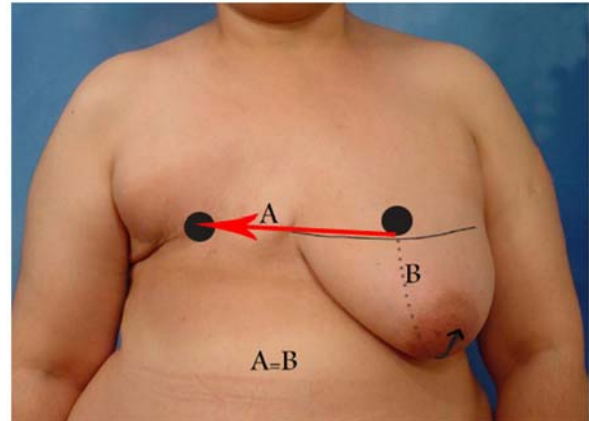


Figure 1. It represents the method of application of cutaneoglandular flap from contralateral breast.

If the distance from crease to nipple in normal breast (line B) is equal or more than the distance from normal breast crease to the predicted nipple location in the operated breast, this flap is applicable.

The patient has been followed for two years and the results are good.

## Discussion

The most common techniques for breast reconstruction share a common donor site, the lower abdomen.

Although TRAM flap is considered the choice for breast reconstruction after mastectomy, it has been criticized for its donor-site morbidity.

Major contraindications of lower abdominal flaps include inadequate soft tissue volume, previous abdominoplasty, lower paramedian scars or multiple abdominal scars [3,16].

Many reconstructive surgeons also consider the TRAM flap to be contraindicated for patients planning for future pregnancy [17].

The major disadvantage of the superior gluteal myocutaneous flap is its short pedicle (3 to 5 cm) which often leads to the use of vein grafts[18,19].

Another disadvantage of the gluteal flaps is the need to change the patient's position during such flap operations.

A pedicled latissimus dorsi flap augmented by a small prosthesis can be an option. However, the use of prosthesis in postmastectomy reconstruction usually results in a poor aesthetic outcome because of capsular contracture and leakage as a result of degradation of the silicone bladder over time. For young patients, one or more implant exchanges may be required over the course of a lifetime [3].

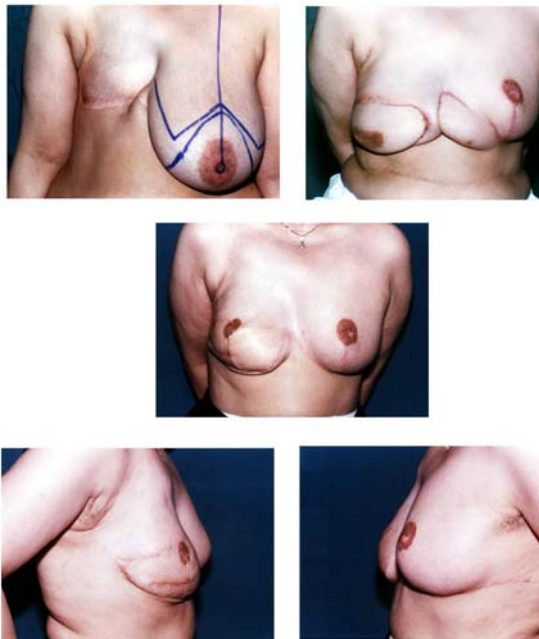


Figure 2. A. It represents the mastectomized site in a 48 year-old female before cutaneo-glandular flap application.

B. 3-weeks after the first operation and before transaction of the pedicle of the flap is shown.

C, D, E. 3 years after transaction of the pedicle of the flap and application of conchal cartilage for nipple reconstruction.

Our method in breast reconstruction after mastectomy offers several advantages:

- It can be used when abdominal scars and other problems contraindicate use of abdominal flaps such as TRAM.
- Reconstruction is done by use of normal breast tissue from the other side.
- It reduces the volume of the large and pendulous breast a patient may suffer from.
- It is almost without donor site morbidity.
- It can be used when the patient cannot tolerate or is not willing to undergo a big operation.
- One of the disadvantages may be the long time follow-up required for diagnosis of possible future malignancy.
- 
- The follow-up can be done by yearly mammography and regular visits and exams.
- In cases such as lobular carcinoma in which the presence of tumor in both breasts is possible, this technique is not used by the authors.

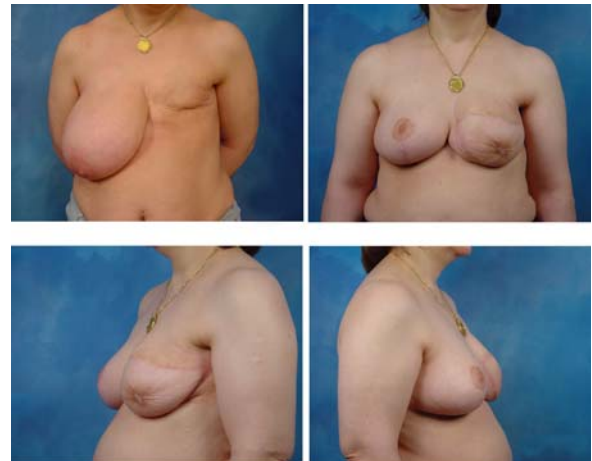

Figure 3. A Location of mastectomized site in a 50 year-old female 2 years after ablative surgery is shown.

B. C. D. Several months after surgery.

## Conclusion

Breast reconstruction with contralateral cutaneous glandular flap after mastectomy may be a good option especially in patients with huge and pendulous breasts.

In addition to reducing the volume of normal but large breast, it uses breast tissue for reconstruction.

This method has several advantages and can be used safely for post-mastectomy breast reconstruction due to cancer.

We have used this technique in 10 patients and with careful and long-time follow-up, have achieved good results.

## References

1. Zhao R, Qiao Q, Yue Y, et al. The psychological impact of mastectomy on women with breast cancer. *Zhonghua zheng Xing Wai Ke Za Zhi*. 2003 Jul; 19(4):294-6.
2. Caffo O, Amichetti M, Ferro A, et al. Pain and quality of life after surgery for breast cancer. *Breast cancer Res Treat*. 2003;80(1):39-48.
3. Serletti JM, Moran SL. Microvascular reconstruction of the breast. *Semin Surg Oncol*. 2000; 19:264.
4. Bruck JC, Kleiner U. Breast reconstruction with the free microvascular abdominal flap: Accessory reconstruction or gold standard? *Zentralb Chir*. 1998;123(suppl.5): 102.
5. Vesely J, Stupka I, Drazan, et al. DIEP flap breast reconstruction: New experience. *Acta Chir Plast*. 2001;43:3.
6. Blondee PN. One hundred free DIEP flap breast reconstructions: A personal experience. *Br J Plast Surg*. 1999;52:104.
7. Lantieri L, Serra M, Dallaserra M, et al. Preservation of the muscle in the use of rectus abdominis free flap in breast reconstruction: From TRAM to DIEP (deep inferior epigastric

perforator) flap- Technical notes and results. *Ann Chir Plast Esthet.* 1997;42:156.

8. Blondeel N, Vanderstraeten GG, Monstrey SJ, et al. The donor site morbidity of free DIEP flaps and free TRAM flaps for breast reconstruction. *Br J Plast Surg.* 1997; 50:322.

9. Arnez ZM, Khan U, Pogorelec D, et al. Rational selection of flaps from the abdomen in breast reconstruction to reduce donor site morbidity. *Br J Plast Surg.* 1999;52:351.

10. Arnez ZM, Khan U, Pogorelec D, et al. Breast reconstruction using the free superficial inferior epigastric artery (SIEA) flap. *Br J Plast Surg.* 1999;52:276.

11. Koshima I, Inagawa K, Yamamoto M, et al. New microsurgical breast reconstruction using free paraumbilical perforator adiposal flaps. *Plast Reconstr Surg.* 2000;106:61.

12. Holmstrom H. The free abdominoplasty flap and its use in breast reconstruction: An experimental study and clinical case report. *scand J Plast Reconstr Surg.* 1979;13:423.

13. Grotting JC, Urist MM, Maddox W, et al. conventional TRAM flap versus free microsurgical TRAM flap for immediate breast reconstruction. *Plast Reconstr Surg.* 1989;83:828.

14. Arnez ZM, Valdatta L, Tyler MP, et al. Anatomy of the internal mammary veins and their use in free TRAM flap breast reconstruction. *Br J Plast Surg.* 1995;48:540.

15. Trabulsy P, Anthony JP, Mathes SJ. Changing trends in postmastectomy breast reconstruction. A 13 year experience. *Plast Reconstr Surg.* 1994;93:1418.

16. Takeishi M, Sha W, Ahn CY, et al. TRAM flaps in patients with abdominal scars. *Plast Reconstr Surg.* 1997;99:713.

17. Chen L, Hartrampf CR, Bennett GK, et al. successful pregnancies following TRAM flap surgery. *Plast Reconstr Surg.* 1993;91:69.

18. Shaw WW. Superior gluteal free flap breast reconstruction. *Clin Plast Surg.* 1998;25:267.

19. Shaw WW. Breast reconstruction by superior gluteal microvascular free flaps without silicone implants. *Plast Reconstr Surg.* 1983;72:490